



PATIENT

Dash Senger

SPECIES

Canine

BREED

Greyhound

SEX

Male Neutered

AGE

10 years

WEIGHT

85.8lbs

INTERPRETED BY

Maggie Machen Lamy,
DVM, DACVIM
(Cardiology)

IMAGING PERFORMED BY

Sarah Pender, CVT

HOSPITAL NAME

SVS Imaging QC

REFERRING VET

Dr. Sullivan

INVOICE

22809

DATE

2/24/22

PRESENTING CLINICAL SIGNS

History: Assess prior to dental. History of prior hepatopathy in Spring 2021, had abdominal ultrasound with SVS at that time, symptoms ended up resolving on denamarin and amoxi/clav.
-Bloodwork: Revealed elevation of ALT (283), AST (64), TBili (0.4), ConjBili(0.2), WBC (9.6), Platelets (239), RBC (9.34), Hematocrit (66.3), Hemoglobin (23.8).

RADIOGRAPHIC FINDINGS *NOTE: Images submitted for supplemental cardiac information only.
Normal cardiac silhouette. No obvious evidence of CHF.

ELECTROCARDIOGRAPHIC FINDINGS *Note: Single lead ECGs are evaluated as a rhythm strip.
Morphology/MEA cannot be definitively commented on.

A single lead ECG is available; 25mm/s, 10mm/mV. The average heart rate is 90bpm (range 65-107bpm). The rhythm is sinus in origin, with a p for every QRS complex and vice versa. The P morphology is positive. The QRS is inverted. A single VPC is identified. No supraventricular premature beats, pauses or other dysrhythmias observed.

ECG diagnosis: Normal sinus rhythm with respiratory variation. Single VPC.

ECHOCARDIOGRAM FINDINGS

2D, m-mode, color flow and doppler imaging is available. Mild diffuse thickening of mitral valve leaflets with no prolapse into the left atrial lumen. No mitral regurgitation with no left atrial dilation. Normal LV diameter with adequate myocardial function. The tricuspid valve appears normal with mild tricuspid regurgitation. Normal TR velocity. Normal right atrial and ventricular diameter and morphology indicating no overt evidence of pulmonary arterial hypertension. The pulmonic and aortic valves are normal in morphology and mobility. Normal pulmonic and aortic outflow velocities with laminar flow. Trace aortic and no pulmonic insufficiency. No pericardial or pleural effusion noted. No obvious cardiac masses.

CARDIAC CHART

CANINE CARDIAC PARAMETERS	MR VMAX (m/s)	TR VMAX (m/s)	LA/AO (Boon method)	LA/AO (Heart Base; Swe)	FS (%)	EF (%)	EPSS (cm)
NORMAL PARAMETER	4.5-5.5	<2.7	1.3	<1.6	28-40	40-100	<0.6
PATIENT	NA	2.5	NM	1.2	40	70	0.58
CANINE CARDIAC PARAMETERS	HR (BPM)	AV VMAX (m/s)	PV MAX (m/s)	BODY WEIGHT (kg)	LA 2D short axis Base view (cm)	LVIDd Avg; 2D and m-mode short axis (cm)	LVIDs Avg; 2D and m-mode short axis (cm)
NORMAL PARAMETER	50-100	0.7-1.7	0.7-1.6	BELOW	BELOW	BELOW	BELOW
PATIENT	133	1.2	0.9	38.9	3.5	4.3	2.6
*Normal chamber parameters expressed as a mean value (SD)				3	1.27 (5.3)	2.46 (2.46)	1.36 (5.5)
BODY WEIGHT DEPENDENT PARAMETERS				5	1.40 (4.5)	2.74 (5.2)	1.60 (4.7)
*Note: All measurements based upon multi-modal images and methods. An average value is reported.				10	1.50 (3.8)	3.27 (3.5)	2.06 (3.1)
				15	1.83 (2.0)	3.71 (2.4)	2.43 (2.1)
				20	2.02 (1.9)	4.14 (2.2)	2.80 (2.0)
				25	2.18 (2.4)	4.48 (2.9)	3.10 (2.5)
				30	2.33 (3.3)	4.83 (3.9)	3.39 (3.4)
				35	2.48 (4.3)	5.17 (5.0)	3.69 (4.5)

Adapted from June Boon, Veterinary Echocardiography, 1998
Rishniw M and Hollis NE, J Vet Intern Med 2000; 14:429-435
Hansson et al, Vet Rad and Ultrasound 2002

**PATIENT**

Bonagura et al. Echocardiography: principles of interpretation, Vet Clin North Am 15:1177, 1995	40	2.62 (5.2)	5.48 (6.1)	3.96 (5.4)
	50	2.88 (7.1)	6.07 (8.3)	4.46 (7.4)

Dash Senger

SPECIES

Canine

BREED

Greyhound

SEX

Male Neutered

AGE

10 years

WEIGHT

85.8lbs

INTERPRETED BYMaggie Machen Lamy,
DVM, DACVIM
(Cardiology)**IMAGING PERFORMED BY**

Sarah Pender, CVT

HOSPITAL NAME

SVS Imaging QC

REFERRING VET

Dr. Sullivan

INVOICE

22809

DATE

2/24/22

INTERPRETATION OF THE FINDINGS & FURTHER RECOMMENDATIONS

Overtly normal cardiac structure and function. The dimensions, function and valve morphology is normal. A small tricuspid leak is identified; however, pulmonary pressures measure normal. No obvious cardiac tumors were identified; however, it should be noted that small epicardial or pericardial masses are easily missed without the presence of effusion. Chest radiographs are also unremarkable in this patient.

These findings would suggest P wave abnormalities are a normal variant. That being said, the ECG did show a single ventricular premature contraction (VPCs). VPCs are generated from abnormal conductive or fibrotic tissue in the ventricles of the heart muscle, and even frequent single VPCs will often cause no clinical signs in dogs. When sustained however, ventricular tachycardia can lead to symptoms such as lethargy and collapse.

VPCs are a very non-specific finding. They can be primary (a rule out diagnosis), secondary to significant cardiac disease (not present in this study) or be extra-cardiac in origin, i.e., due to pain, stress, inflammation, cancer, GI disease, DIC/sepsis, etc. In a senior dog, all differentials should be ruled out although a normal stress response is suspected. A repeat abdominal ultrasound can be considered to monitor for any changes. Additionally, a thoracic CT can be considered to screen for masses or abnormalities too small to find easily on echocardiogram. Suspicion is low in this case. Unfortunately, there is always an elevated risk for collapse and sudden death in any arrhythmic patient, and even on medications this risk unfortunately still persists. All that being said, only a single abnormal beat is identified, and simple monitoring is also reasonable.

Based strictly upon the amount of arrhythmia present on the available ECG, anti-arrhythmic therapy is not clearly indicated. Only single VPCs are seen, which is a low marker of malignancy. A holter monitor can be considered to allow monitoring of the rhythm throughout 24 hours of a normal day and help determine if treatment is indicated.

Fish oil supplementation is recommended for dogs with arrhythmias (500-1000mg of omega 3 and 6 once to twice daily).

Monitor at home for collapse, exercise intolerance, and/or lethargy. Mild activity restriction is advised. If a holter monitor is elected, this will dictate whether therapy is needed and follow up protocol.

Anesthetic risk is considered moderately elevated. Avoid ketamine, telazol, Dexdomitor (or other alpha-2 agonists) and acepromazine. Recommend having lidocaine CRI available for use in the event of worsening ventricular arrhythmias under anesthesia (CRI 50–75mcg/kg/min).

Going forward, a recheck ECG and echocardiogram is recommended in 6 months to screen for any changes and reassess arrhythmia, sooner if any clinical signs develop or a heart murmur is noted.

IMAGING PERFORMED BY

svsmobileimaging.com 309-737-3070



Clinical Sonography & Telecytology

EDUCATIONAL TELECONSULTATION SERVICES™

1-800-838-4268 info@sonopath.com SonoPath.com

PATIENT

Dash Senger

SPECIES

Canine

BREED

Greyhound

SEX

Male Neutered

AGE

10 years

WEIGHT

85.8lbs

INTERPRETED BY

Maggie Machen Lamy, DVM, DACVIM (Cardiology)

IMAGING PERFORMED BY

Sarah Pender, CVT

HOSPITAL NAME

SVS Imaging QC

REFERRING VET

Dr. Sullivan

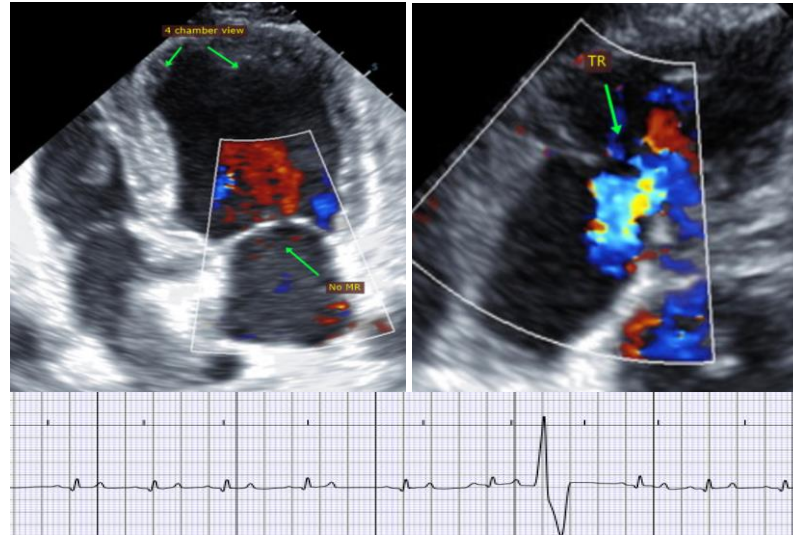
INVOICE

22809

DATE

2/24/22

IMAGES



The information and recommendations provided are based on the images presented by the referring veterinarian. No evaluation can be communicated regarding pathology that was not visible in the image/video clips provided.

Thank you for this referral. If the clinical or image interpretation does not parallel your findings or if I can be of any further assistance, please contact me.

Maggie Machen Lamy, DVM
Diplomate of the American College of Veterinary Internal Medicine (Cardiology)
info@sonopath.com